



PATIENT

Paquito Maldonado

SPECIES

Canine

BREED

Yorkshire Terrier

SEX

Male Neutered

AGE

5.11 years

WEIGHT

14.8lbs

INTERPRETED BY

Maggie Machen Lamy,
DVM, DACVIM
(Cardiology)

IMAGING PERFORMED BY

G. Ferrer, DVM

HOSPITAL NAME

Pulse: Pet Ultrasound
Services

REFERRING VET

Dr. Alverio

INVOICE

45781

DATE

11/17/25

PRESENTING CLINICAL SIGNS

History: CXR showed cardiomegaly. Possible reverse sneezing. Loss of breath. Assess prior to anesthesia.

RADIOGRAPHIC FINDINGS *NOTE: Images submitted for supplemental cardiac information only. Subjective cardiomegaly; however, the VHS is normal. No obvious evidence of CHF.

ELECTROCARDIOGRAPHIC FINDINGS

A six lead ECG is available at 25mm/s; 5mm/mV. The average heart rate is 120bpm. The rhythm is sinus in origin, with a p for every QRS complex and vice versa. The P wave morphology is positive with a normal dimension. Normal PR. The QRS morphology is positive with normal dimension. MEA is normal. No ectopic beats, pauses or dysrhythmias observed. ECG diagnosis: Normal sinus rhythm with respiratory variation.

ECHOCARDIOGRAM FINDINGS

2D, m-mode, color flow and doppler imaging is available. Thickened mitral valve leaflets with no significant prolapse into the left atrial lumen. No mitral regurgitation with no left atrial dilation. Normal LV diameter with adequate myocardial function. The tricuspid valve appears normal with no obvious tricuspid regurgitation. Normal right atrial and ventricular diameter and morphology indicating no overt evidence of pulmonary arterial hypertension. The pulmonic and aortic valves are normal in morphology and mobility. Normal pulmonic and aortic outflow velocities with laminar flow. No obvious aortic or pulmonic insufficiency. No pericardial or pleural effusion noted. No obvious cardiac masses.

CARDIAC CHART

CANINE CARDIAC PARAMETERS	MR VMAX (m/s)	TR VMAX (m/s)	LA/AO (Boon method)	LA/AO (Heart Base; Swe)	FS (%)	EF (%)	EPSS (cm)
NORMAL PARAMETER	4.5-5.5	<2.7	1.3	<1.6	28-40	40-100	<0.6
PATIENT	NA	NA	NM	1.3	36	67	0.2
CANINE CARDIAC PARAMETERS	HR (BPM)	AV VMAX (m/s)	PV MAX (m/s)	BODY WEIGHT (kg)	LA 2D short axis Base view (cm)	LVIDd Avg; 2D and m-mode short axis (cm)	LVIDs Avg; 2D and m-mode short axis (cm)
NORMAL PARAMETER	50-100	0.7-1.7	0.7-1.6	BELOW	BELOW	BELOW	BELOW
PATIENT	110	0.8	0.9	6.7	1.8	2.5	1.6
*Normal chamber parameters expressed as a mean value (SD)				3	1.27 (5.3)	2.46 (2.46)	1.36 (5.5)
BODY WEIGHT DEPENDENT PARAMETERS				5	1.40 (4.5)	2.74 (5.2)	1.60 (4.7)
*Note: All measurements based upon multi-modal images and methods. An average value is reported.				10	1.50 (3.8)	3.27 (3.5)	2.06 (3.1)
				15	1.83 (2.0)	3.71 (2.4)	2.43 (2.1)
				20	2.02 (1.9)	4.14 (2.2)	2.80 (2.0)
				25	2.18 (2.4)	4.48 (2.9)	3.10 (2.5)
				30	2.33 (3.3)	4.83 (3.9)	3.39 (3.4)
				35	2.48 (4.3)	5.17 (5.0)	3.69 (4.5)
				40	2.62 (5.2)	5.48 (6.1)	3.96 (5.4)
				50	2.88 (7.1)	6.07 (8.3)	4.46 (7.4)

Adapted from June Boon, Veterinary Echocardiography, 1998
Rishniw M and Hollis NE, J Vet Intern Med 2000; 14:429-435
Hansson et al, Vet Rad and Ultrasound 2002
Bonagura et al. Echocardiography: principles of interpretation, Vet Clin North Am 15:1177, 1995



PATIENT

Paquito Maldonado

SPECIES

Canine

BREED

Yorkshire Terrier

SEX

Male Neutered

AGE

5.11 years

WEIGHT

14.8lbs

INTERPRETED BY

Maggie Machen Lamy,
DVM, DACVIM
(Cardiology)

IMAGING PERFORMED BY

G. Ferrer, DVM

HOSPITAL NAME

Pulse: Pet Ultrasound
Services

REFERRING VET

Dr. Alverio

INVOICE

45781

DATE

11/17/25

INTERPRETATION OF THE FINDINGS & FURTHER RECOMMENDATIONS

Overtly normal cardiac dimensions and function, with no obvious dysfunction or dilation of the left heart. No significant valvular leaks are visualized, and no evidence of pulmonary hypertension. The MV is mildly thickened which may reflect early valve disease, and follow up is advised should a murmur develop. The ECG is unremarkable with a respiratory sinus arrhythmia.

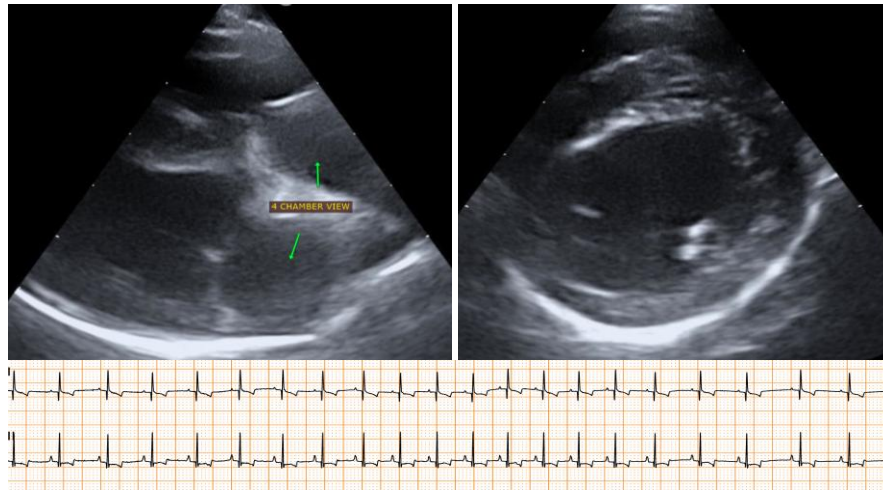
These findings would suggest the radiographic appearance is likely a normal variant. These films should be used as a baseline for future comparison.

No medications are indicated and the prognosis is open from a cardiac standpoint.

Monitor for development of a heart murmur, cough, labored breathing, exercise intolerance or collapse episodes.

A recheck echocardiogram is recommended should a significant murmur develop or signs of cardiac compromise be noted in the future.

IMAGES



The information and recommendations provided are based on the images presented by the referring veterinarian. No evaluation can be communicated regarding pathology that was not visible in the image/video clips provided.

Thank you for this referral. This report was generated using transcription software, and minor dictation errors may be present. If the clinical or image interpretation does not parallel your findings or if I can be of any further assistance, please contact me.

Maggie Machen Lamy, DVM
Diplomate of the American College of Veterinary Internal Medicine (Cardiology)
info@sonopath.com